



eaglet-eye

OVITZ®

WHEN PRECISION MEETS INNOVATION

Eye Surface Profiler and xwave Aberrometry System

We create the extraordinary

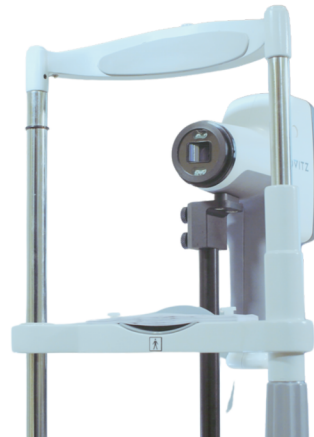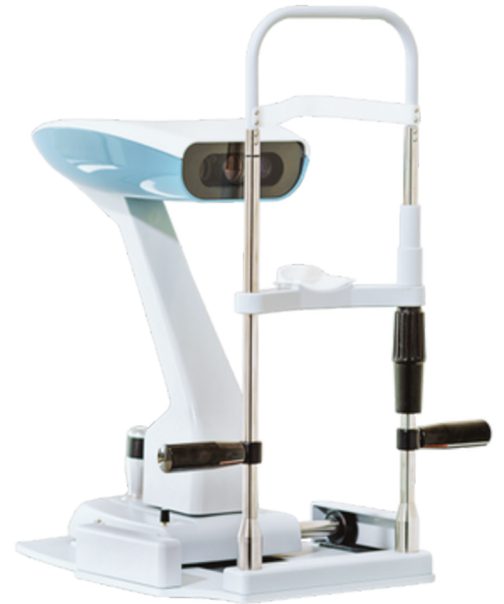"Corneo-scleral profilometry and the ability to precisely correct the uniquely imperfect optics of the eye are game changers for eye care. The capability to confidently design custom lenses for any ocular surface condition enhances practice outcomes and takes contact lens fitting to the highest level. To not only identify and quantify HOA but to actually correct for them individually transforms both practices and patients' lives. Many patients, after years of poor-quality vision despite previous best efforts, can now experience clarity and comfort like never before. The growing compatibility of precise lens fitting with HOA correction finally allows patients to achieve their best vision and live fuller lives, while giving practitioners the satisfaction of making a tremendous difference in our patients' quality of life."

Dr. Aaron Wolf, OD, FAAO, FSLs, FIAOMC
Austin Optometry Group, Austin, TX, USA



SCLERAL LENSES
FOR HOA CONTROL
HAVE NEVER BEEN
MORE SUCCESSFUL

OVITZ[®]
xwave

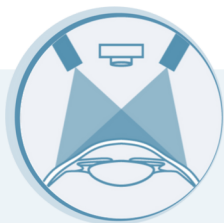



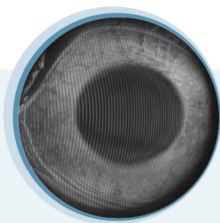
TRANSFORMING SPECIALTY LENS FITTING

The Eye Surface Profiler offers unmatched accuracy in corneo-scleral profilometry. Achieve faster, personalized, and more precise lens fittings.

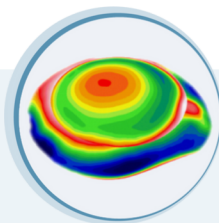
It is crucial to achieve a stable scleral lens fit prior to attempting aberration correction. Leveraging the ESP's advanced data reduces the need for multiple fittings, optimizing chair time and providing a better patient experience.



Fast, single shot measurements provide highly precise elevation data with no extrapolation or stitching.



High-density data of the full cornea, limbus to limbus, and sclera, for advanced precision.



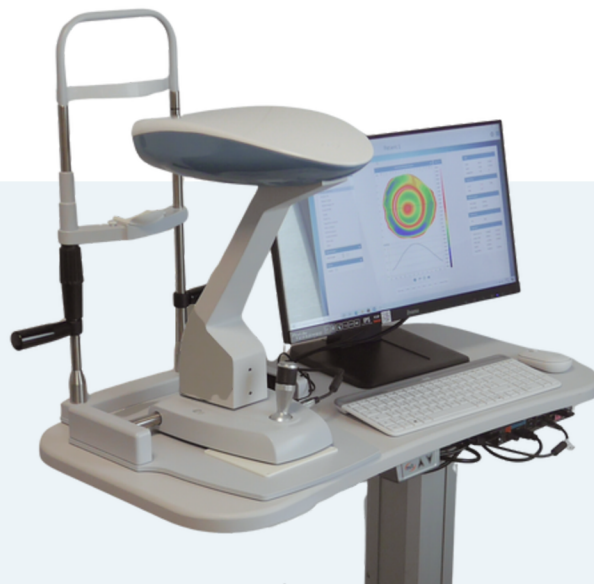Advanced algorithms ensure optimal fit and comfort, tailoring each lens perfectly to the patient.

WORKS WITH ALL LEADING LENS DESIGNS

The Eye Surface Profiler is an open platform that integrates seamlessly with all lens manufacturers. Select the best lenses for your patients without restrictions, you hold the power in your hands!

First Lens Fit algorithms: The integrated algorithms take the guesswork out of contact lens fitting. They automatically calculate all essential lens parameters, ensuring a perfect fit every time.

Fully customized lenses: With 500,000 data points capturing every detail of the eye's surface, the ESP brings the precise, detailed data demanded by freeform lenses.

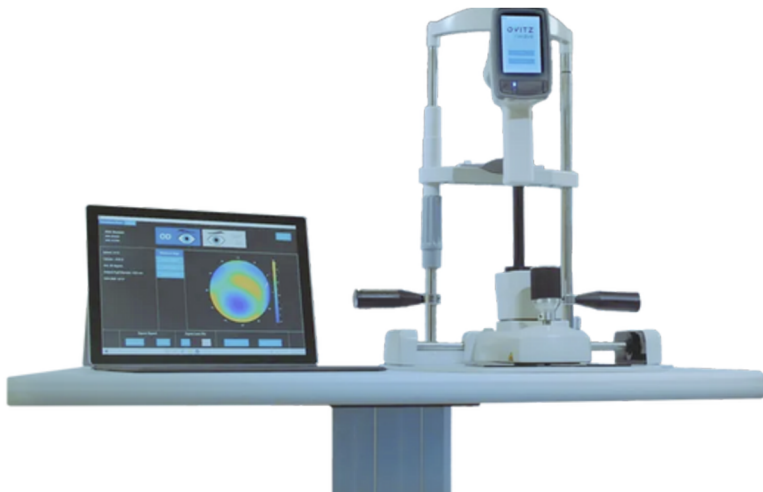


MEET THE XWAVE SYSTEM

Higher-Order Aberration Correction Taken to a New Level

Combining advanced wavefront aberrometry measurement seamlessly with lens manufacturer lathe machine software, OVITZ xwave delivers the world first closed-loop wavefront guided contact lens production system.

Its user-friendly design and interface means it's incredibly easy to use. Optometrists or technicians can be up and running with the device in literally minutes.



OVITZ[®] xwave

WAVEFRONT CORRECTION. MADE EASY.

Correcting Higher Order Aberrations (HOA) has never been easier and more effective.

HOW IT WORKS

Deliver Life-changing Vision Improvements

- MEASUREMENT**
The unique xwave Aberrometer records a complete ocular measurement.
- ANALYSIS**
A comprehensive analysis is calculated and automatically processed.
- DESIGN**
An HOA optic is created by a proprietary design algorithm and sent to the manufacturing lab.
- MANUFACTURE**
The scleral lens powered by the OVITZ HOA optic is manufactured by the lab.

CASE 1 | Post-LASIK Ectasia

By Dr. Barry Leonard

Patient History

A 52-year-old female presents to the clinic for post LASIK ectasia management on her right eye.

She works as a technician at an ophthalmic office and had undergone Monovision LASIK 14 years ago. Correcting her right eye for perfect full-distance vision, while leaving her left eye myopic, creates blended visual focal points and allows the patient to enjoy good vision from both near and far.

Her vision was decent initially but got worse with time, so she underwent an enhancement 3 years after her initial surgery. Over the past years, the vision in the right eye had become progressively more blurred, and post-refractive ectasia was diagnosed.

The patient was referred for a scleral contact lens fit for OD only, keeping the left eye myopic for near monovision.

SPECTACLE REFRACTION

OD: +0.50 -2.75 x 67 20/60

OS: -2.25 -0.25 x 160 20/20

Scleral Lens with HOA correction

Post-LASIK ectasia can present significant visual challenges, primarily due to the irregular astigmatism and resulting Higher-Order Aberrations (HOAs), often requiring advanced optical solutions. Scleral lenses have become a leading non-surgical option for managing these complex corneal irregularities. Additionally, they can incorporate wavefront technology to effectively reduce HOAs.

Scleral Lens Fitting with Corneo-Scleral Profilometry

The ESP directly measures sagittal height and creates detailed maps, enabling the visualization of the corneal and scleral shapes as well as areas of elevation and depression. The ESP data revealed an irregular scleral pattern (Figure 1).

Due to the asymmetry of the cornea and sclera, a customized freeform lens was selected. It is crucial to first achieve a stable scleral lens fit prior to attempting aberration correction. Leveraging the ESP's advanced data reduces the need for multiple fittings, optimizing chair time and providing a better patient experience.

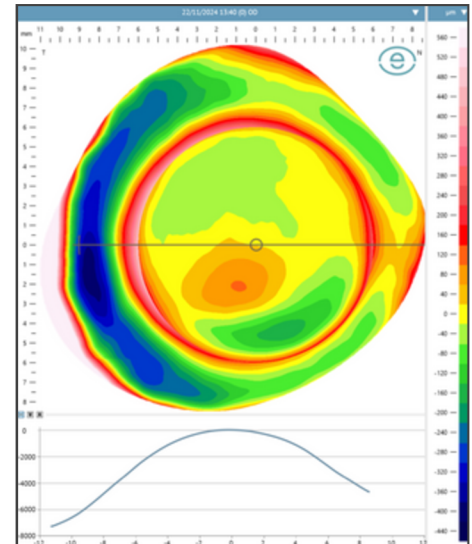


Figure 1 ESP Bisphere elevation map.

Higher-Order Aberration Correction with xwave System

Based on the ESP height data, a freeform GAUDI (Valley Contax, USA) scleral lens was designed: OD 7.85 -0.75 16.4 .3ct. This baseline custom lens with a series of alignment markings (Figure 2) is then used to perform the HOA fitting process. The marked lens was stable and provided an optimized fit, so no modifications were needed before proceeding with the measurements.

After a complete ocular measurement with OVITZ xwave aberrometer, a new scleral lens powered by the OVITZ HOA optic was ordered. No further adjustments were needed and the patient achieved visual acuity of 20/20 in her right eye with the first HOA lens (Figure 3). The most severe HOA, Coma (Z7), which is known to cause visual distortions resembling double vision, exceeded $0.6\mu\text{m}$, a level considered severe, with a baseline scleral lens but was corrected to a subclinical value of $0.1\mu\text{m}$ once the OVITZ HOA optic was added to the lens.

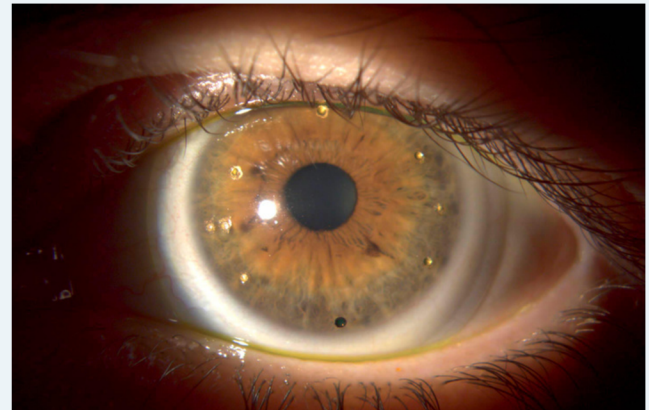


Figure 2 Baseline scleral lens with markings.

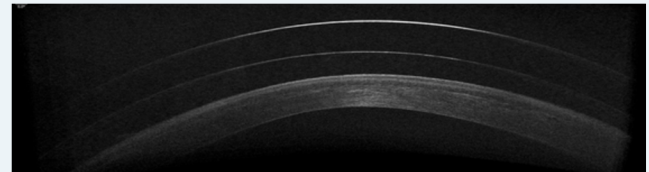


Figure 3 Cross-sectional OCT images of the right eye.

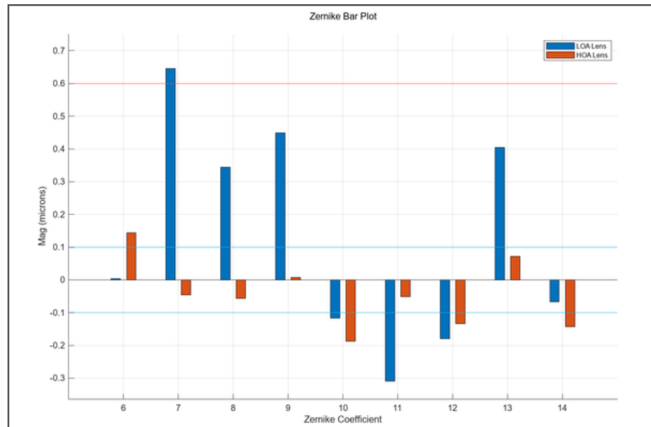


Figure 4 HOA RMS reduced from 1.02 to $0.32\ \mu\text{m}$ (a 69% reduction).

CONCLUSION

Profilometry-driven freeform scleral lenses together with wavefront-driven HOA corrected optics present the future of vision correction. The designed custom scleral lens using these technologies was highly effective in reducing HOAs in this patient with irregular cornea due to the Post-LASIK ectasia.

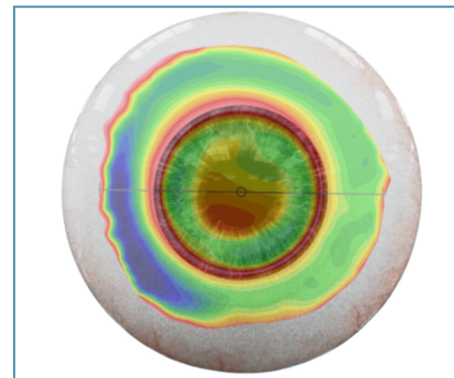
WHEN PRECISION MEETS INNOVATION

Eye Surface Profiler and xwave System

Scleral lenses are now a standard refractive correction option for patients with significant aberrations, such as post-refractive surgery ectasia, post-penetrating keratoplasty, corneal trauma, pellucid marginal degeneration, and keratoconus.

We are in a new era of customized scleral contact lenses, driven by advanced technologies like Profilometry and wavefront-guided optics. This powerful combination is set to improve both comfort and visual outcomes for patients.

Device-driven solutions like these are revolutionizing care and offering new ways to improve the lives of those with complex vision needs.



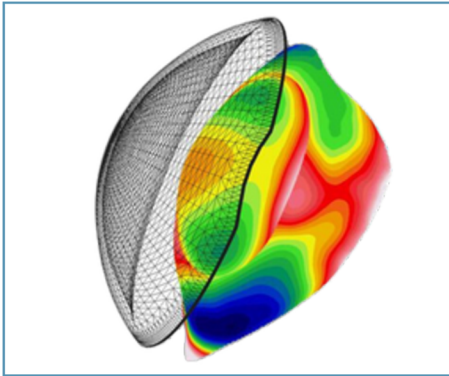
Complete Corneo-Scleral Measurement

Scleral shapes are highly irregular, precise ocular mapping is essential.

TOTAL FREEDOM

Scleral contact lenses are ideally suited to customize HOA correction because – when appropriately fitted – they remain stable on the eye. OVITZ has demonstrated superior patient satisfaction and reduction in HOA using the OVITZ wavefront-guided HOA optics when combined with stable, well-fitted scleral lenses.

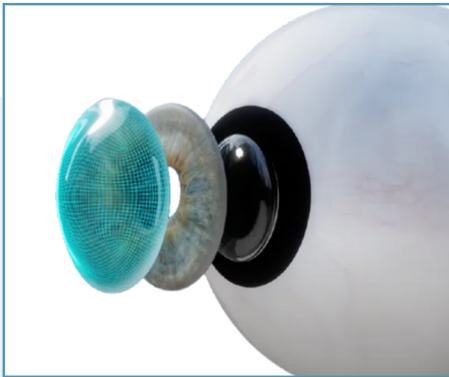
- Corneo-scleral profilometry data to personalize the back surface landing zone.
- Precise wavefront-guided correction for customized optics at the front surface.
- Your lens, your choice—Ovitz and Eaglet Eye are open, lab-neutral platforms.



By combining ESP Profilometry data with OVITZ xwave Aberrometry (Wavefront) data you can create even more precise scleral lenses for HOA correction. This leads to better vision and happier patients.

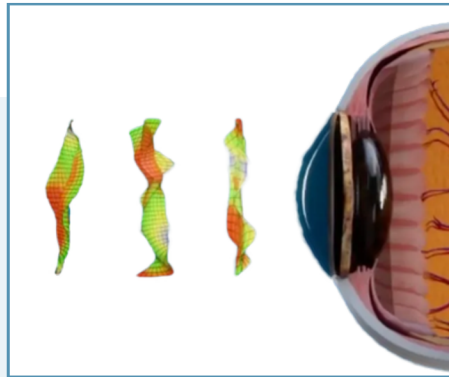
Well Centred and Stable Scleral Fit

Leveraging the ESP's advanced data reduces the need for multiple fittings.



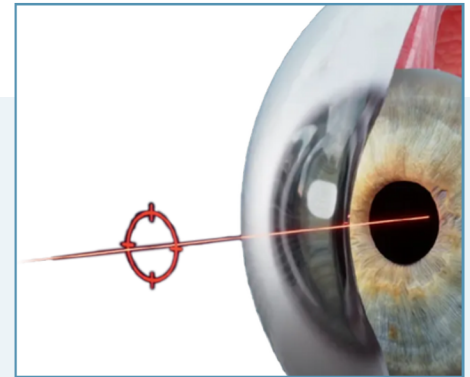
Complete Ocular HOA Measurement

Corneal HOA alone is not enough, we measure the entire visual system.



Proprietary HOA Lens Design Algorithm

Using the patient's HOA profile and eye data to create a custom HOA lens design.



Precise Correction on the Accurate Axis

Submillimeter differences can be crucial for an outstanding outcome.

CASE 2 | Ehlers-Danlos Syndrome

By Dr. Sheila Morrison

Patient History

A 24-year-old female with Keratoconus and Ehlers-Danlos Syndrome (EDS). She had undergone wavefront PRK with corneal crosslinking to manage keratoconus which had onset 2 years prior and presented with irregular, ectatic corneas.

The patient had NON-SATISFACTORY 20/30 vision in both eyes and suffered from monocular diplopia and ghosting, more acutely on the left eye. Standard front surface toric scleral lenses were fitted but did not resolve her visual disturbances or provide adequate vision.

SPECTACLE REFRACTION

OD: +0.75-2.00x104 20/30

OS: +1.25-2.00x069 20/30

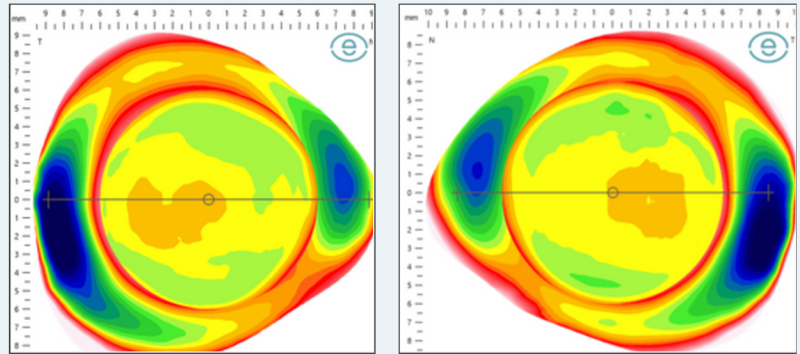


Figure 1 ESP Bisphere elevation maps OD/OS.

The fit was as empirical as possible with current technology with a fast and easy back-surface design. Lens centration and rotational stability are crucial for a successful HOA correction. The baseline custom lenses with markings were ordered (Figure 2) for the HOA fitting process. No adjustments were needed for the lens shape.

Data-Driven Freeform Scleral Lenses

Profilometry scans were taken with the Eye Surface Profiler. In a single shot image, with no stitching or extrapolation, the ESP provides a very high level of precision when creating corneo-scleral maps.

The ESP's Bisphere elevation maps revealed 'against-the-rule' scleral toricity, and irregular corneal astigmatism (Figure 1). A ScanFitPRO freeform scleral lens (EyePrint Prosthetics, USA) was digitally designed from the ESP measurements.

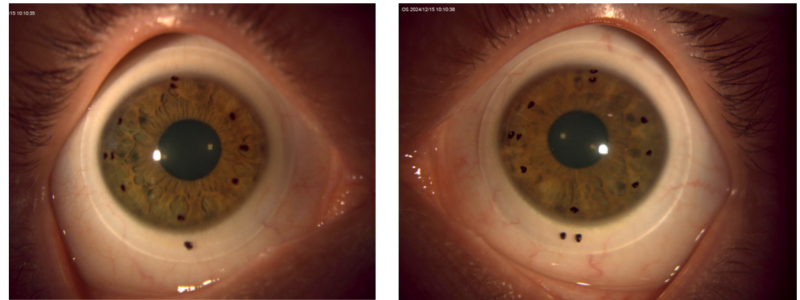


Figure 2 ScanFitPRO baseline scleral lenses with markings OD/OS.

Wavefront-Driven Higher Order Aberration Correction

After a complete ocular measurement with the OVITZ xwave aberrometer, the new scleral lenses powered by the HOA optic were manufactured. The HOA data indicates that HOAs are relatively well corrected, as shown in the plots (Figure 3):

- HOA RMS reduced from 1.12 to 0.7 μm (a 38% reduction) for OD.
- HOA RMS reduced from 1.42 to 0.45 μm (a 69% reduction) for OS.

After two additional HOA optic lens adjustments and some time for neuroadaptation the resulting lenses gave the patient sharp vision OD 20/25 and OS 20/20 with significant decrease of ghosting and diplopia.

CONCLUSION

For patients with complex conditions such as Keratoconus and Ehlers-Danlos Syndrome, scleral lenses designed with profilometry data and wavefront-guided HOA correction offer exceptional visual rehabilitation. In this case, the combination of ESP profilometry and OVITZ xwave technology successfully addressed the patient's diplopia and ghosting, delivering clear and stable vision.

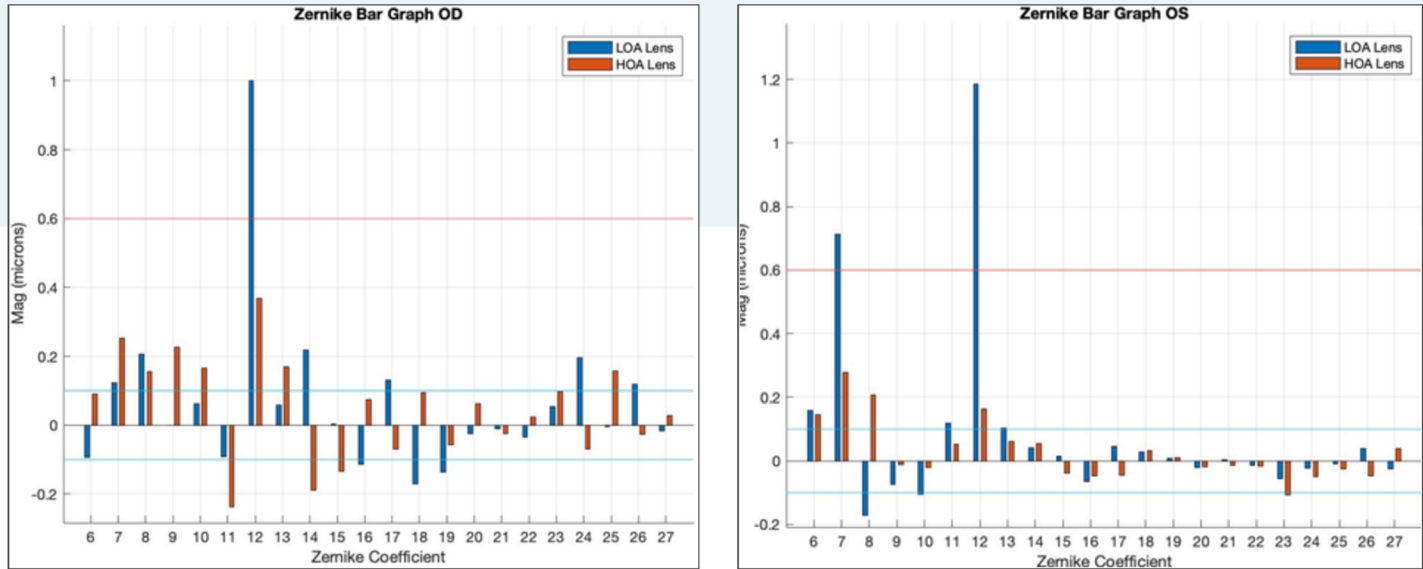


Figure 3 Comparison of individual Zernike polynomials from the OVITZ xwave System (Baseline scleral lens to final HOA lens).

CASE 3 | Severe Higher-Order Aberration

By Dr. Aaron Wolf

Patient History

A 25-year-old Caucasian female with keratoconus in both eyes presented following bilateral corneal collagen cross-linking (CXL) performed in 2023.

Despite the procedure's success in stabilizing the corneas, she continued to experience severe higher-order aberrations (HOAs) resulting in poor visual quality.

Rotational Stability Challenge

One of the primary challenges in this case was the minimal scleral toricity in each eye of approximately $100\mu\text{m}$ observed in the patient's ocular surface at a 15mm chord (Figure 1). The low toricity may not be sufficient to keep a conventional scleral lens rotationally stable, making them unsuitable for effective HOA correction. Without proper stabilization, the lens rotation would compromise the alignment necessary for precise optical performance.

Profilometry scans with the Eye Surface Profiler (ESP) were taken. Each measurement contains over half a million data points, which allowed to design GAUDI (Valley Contax, USA) freeform scleral lenses with enough nuanced elevation changes to align with the scleral shape, effectively 'locking in' the lens to all the minimal geographic variations available, providing the necessary rotational stability (Figure 2).

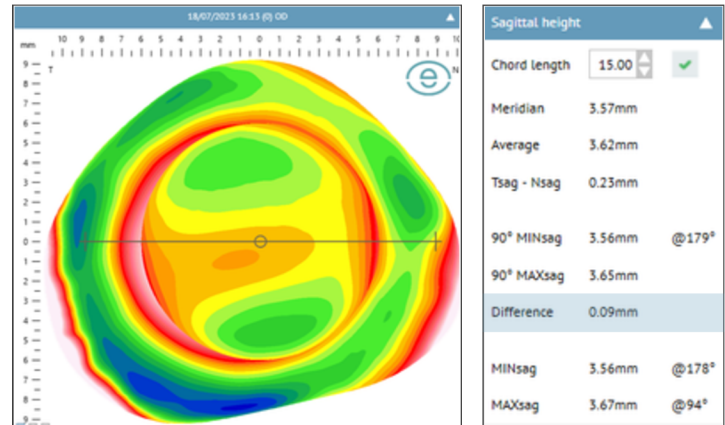


Figure 1 ESP Bisphere Elevation map and sagittal calculator for the right eye.

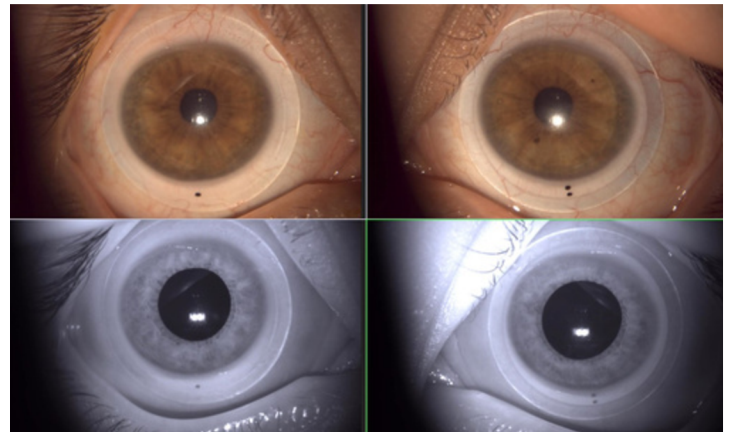


Figure 2 Color and infrared photos of the final lenses demonstrating good alignment and centration on both eyes.

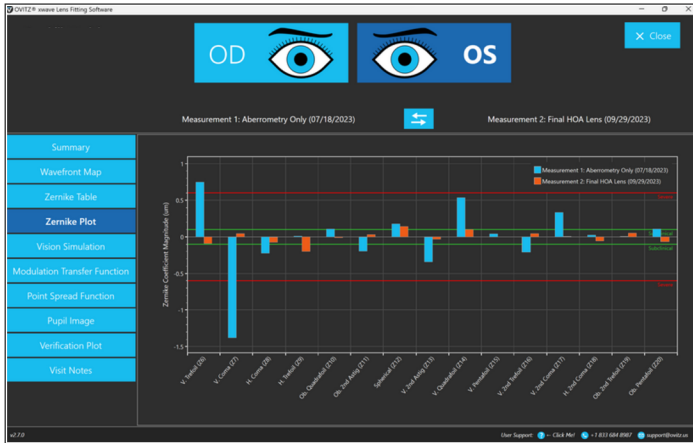
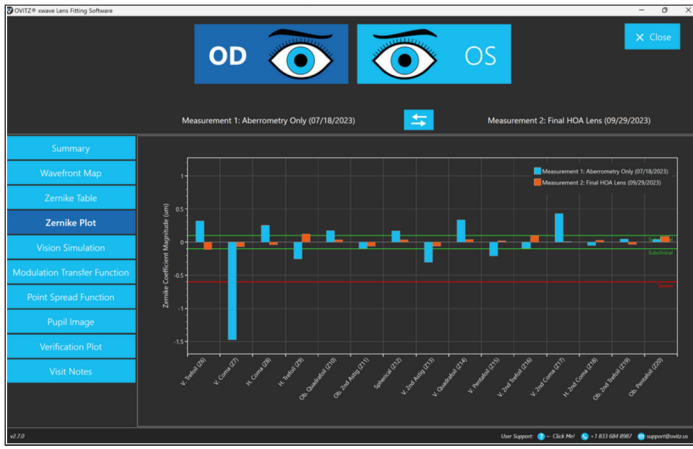


Figure 3 Comparison of individual Zernike polynomials from the OVITZ xwave System, Baseline scleral lens to Final HOA lens, OD/OS.

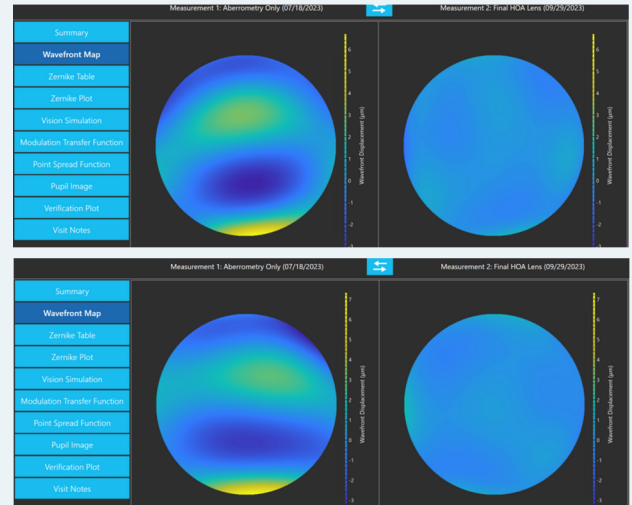


Figure 4 Wavefront map, Baseline lens to Final HOA lens, OD/OS.

CONCLUSION

Achieving rotational stability through profilometry-driven lens customization enabled precise alignment for effective HOA correction. The results speak for themselves: vision improved to 20/25 OD and 20/20 OS, with a remarkable reduction in HOA RMS—approximately sevenfold in the right eye and eightfold in the left. This case underscores the power of advanced technologies like profilometry and wavefront optics to transform vision care for patients with complex corneal conditions, regardless of scleral topography challenges.

“Advancements in scleral profilometry and HOA have redefined the way we fit scleral lenses. Accurate mapping of the eye’s shape and optics facilitates creation of devices that enhance comfort and sight. Improved optical outcomes and reduced visual disturbances drive exceptional patient satisfaction, referrals to our practice, and solidifies our leadership in cutting-edge vision care.”

Dr. Sheila Morrison, OD, MS, FAAO, FSLC
Mission Eye Care, Calgary, Canada



“Corneo-scleral profilometry and HOA control have transformed patient care in our practice. Precise scleral mapping allows for customized lens fittings that improve visual acuity and comfort, especially for conditions like keratoconus or other corneal conditions. Incorporating HOA control enhances optical quality, reducing glare and halos, leading to higher patient satisfaction. This dual approach has boosted referrals, established our practice as a leader in advanced vision correction, and elevated our standard of care.”

Dr. Barry Leonard, OD

California Keratoconus Center, Panorama City, CA, USA



Special thanks to:

Dr. Barry Leonard, OD | California Keratoconus Center, Panorama City, CA, USA

Dr. Sheila Morrison, OD, MS, FAAO, FSLS | Mission Eye Care, Calgary, Canada

Dr. Aaron Wolf, OD, FAAO, FSLS, FIAOMC | Austin Optometry Group, Austin, TX, USA



eaglet-eye

OVITZ®



Eaglet Eye B.V.

info@eaglet-eye.com
www.eaglet-eye.com

Ovitz

info@ovitz.us
www.ovitz.us